

# SURVEY ON A HYBRID APPROACH OF DETECTION OF GLAUCOMA USING SDC BASED METHOD AND LBP FEATURES

Sowmya J Prakash<sup>1</sup>, Fenita<sup>2</sup>

<sup>1</sup>M.Tech Student, Department of CSE, The Oxford College of Engineering, Bangalore, Karnataka, India.

*sowmyaparakash92@gmail.com*

<sup>2</sup>Assistant Professor, Department of CSE, The Oxford College of Engineering, Bangalore, Karnataka, India.

*fenita87@gmail.com*

## Abstract

Glaucoma is an extreme eye illness that prompts visual deficiency by expansion in weight at the dividers of the front eye. The glaucoma screening has become a research point in the field of biomedical image processing. The glaucoma detection is very essential factor in preventing the loss of eye sight. At the present day glaucoma screening done for 2D retinal fundus images. This paper addresses the survey on the method called "Container to glass" ratio which is very reliable in detecting the status of the progression of glaucoma disease. It classifies the input image into categories of the disease like normal, moderate and medium based on the computed value of the CGR. The CGR is characterized as the proportion of vertical container distance across to the vertical plate breadth. For control of CGR past calculations like territory of the circle, plate location, extraction of container and the extraction of circle must be finished. Consequently glaucoma screening by container to plate proportion will be extremely proficient technique for screening in vast populace based frameworks. Self assessed disk segmentation is the methodology which consolidates the superpixel division, edge recognition and round hough change. Superpixel era is done utilizing SLIC calculation that makes collection of pixel to frame a superpixel. Edge location is essential element for the identification of the region of container and the plate in the division process. Round about hough change which is an element extraction system used to distinguish the state of the sporadic data picture. From these information we can register glass to circle proportion that is the proportion of vertical container to the vertical plate. It will classify the input image into normal, medium and severe cases. This will be very helpful for the patients to know that in which stage the disease is progressed and they can take some preventive measure against vision loss.

**Keywords:** Container to Glass Ratio, Superpixel Division.

\*\*\*

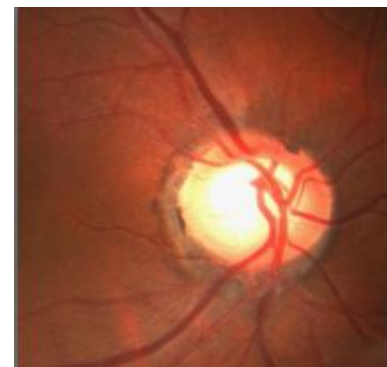## 1. INTRODUCTION

Image processing is a technique that will extract essential features of an image that performs operations like preprocessing, Segmentation, Circular hough transform and normalization. Medical imaging is the technique that is incorporated in this field that creates the visualized form of the interior parts of the human eye for medical examination. In our concept of view we consider "glaucoma eye". Generally there are three methods of detecting the disease:

Intraocular pressure which exerts pressure at the walls of the retinal outline.[2]

Visual field test needs a sensitive examination of inner eye with standard equipments. The technique used called "tonometry".

Optic Nerve Head is the third approach which can promise the glaucoma presence in the eye. It can be done by expertise professionals.



**Figure 1.** Image of glaucoma

The figure 1 shows the sample of input image of the eye that is affected by glaucoma disease. It shows clear separation of blood vessels, cup that is entering the cup area.

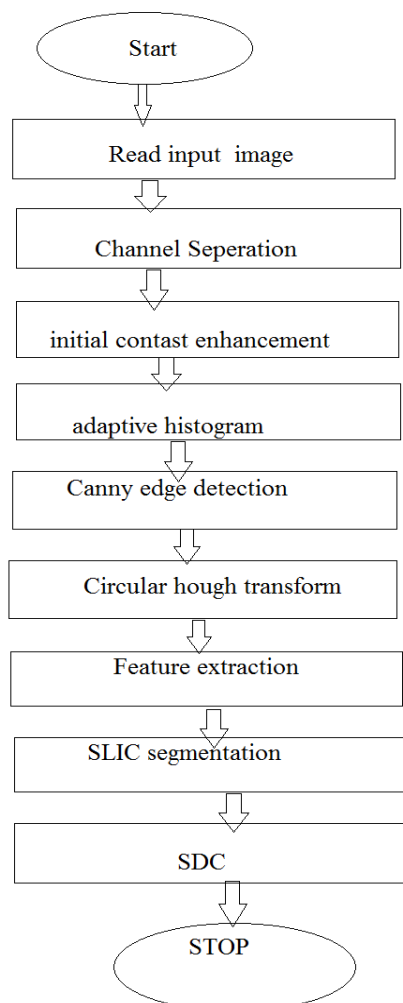
### 1.1 Discussion of Major Causes of the Disease

1. The ailment can be created because of low emission of fluid amusingness to the front parts of the eye.
2. The damage of inner optic nerves which causes loss of peripheral side vision loss of the eye.
3. Enlargement of cup area at the center of the eye can show further symptoms like headache, immediate blurred sensation, vision loss.

## 2. RELATED WORK

As of now the air-puff intraocular pressure(IOP) estimation, visual field test and optic nerve head(ONH) evaluation are frequently utilized as a part of glaucoma appraisal. Be that as it may, the IOP estimation gives low precision in glaucoma discovery and visual field test examination requires unique hardware just present in specific doctor's facilities. Along these lines, they are appropriate for screening in populace. ONH evaluation is all the more encouraging for glaucoma screening. It should be possible by a prepared proficient. However manual appraisal is subjective, tedious and costly. Lately robotized calculations for ONH appraisal have gotten much consideration. There is some exploration into mechanized container to circle ratio(CDR) evaluation from 3-D pictures, for example, stereo pictures and optical cognizance tomography pictures. However the expense of getting 3-D pictures is still high, which makes it unseemly for minimal effort expansive scale screening. The 2-D retinal fundus pictures can be gained at much lower cost on the grounds that such fundus cameras are generally accessible in clinics, polyclinics eye focuses and optical shops. In this way, there is minimal extra equipment expense to assemble a glaucoma screening program utilizing existing fundus cameras.

## 3. WORKFLOW DIAGRAM



**Figure 2.1** Flow chart of CDR

The figure 2.1 explains the flow of logic initially we take an input image and it is subjected to processing. The next step is channel separation that separates red channel, green channel and the blue channel.

The third step is contrast improvement of the grey image. The fourth step is adaptive histogram equalization to get even distribution of grayscale in the input image. Canny edge detection is used to detect the center of the cup which is affected by glaucoma. Circular hough transform reshapes the input image. Feature extraction is used to extract particular feature of the input image. Simple Linear Iterative Clustering form aggregation of pixels that contain pixel with similar properties. The as a result we compute sparse dissimilarity(CDR) as a final result and end.

## 4. LITERATURE SURVEY

[1] "The prevalence and types of glaucoma in Malay people: The Singapore Malay eye study," by S.Y.Shen

Design is to evaluate the predominance and sorts of glaucoma in an Asian Malay population. Methods in Singapore Malay Eye Study is a populace based, cross-sectional review that analyzed 3280 (78.7% reaction) persons matured 40 to 80 years. Members experienced expanded optic circle appraisal.

Members who were suspected to have glaucoma likewise experienced visual field that has taken the examination of 3280 patients database. Glaucoma was characterized by Society for Geographical and Epidemiologic Ophthalmology criteria. Results show that it has given near results for good accuracy.

Conclusion: More than 90% of glaucoma cases were beforehand undetected.

[2] "Automated segmentation of the optic disc from stereo color photographs ," by M. D. Abr'amoff et al.

Early discovery of glaucoma is fundamental to minimizing the danger of visual misfortune. It has been demonstrated that a decent indicator of glaucoma is the glass to-plate proportion of the optic nerve head. This paper shows a robotized strategy to portion the optic circle. Our methodology uses pixel highlight determination to prepare a list of capabilities to perceive the district of the plate. Delicate pixel order is utilized to produce a likelihood guide of the circle. Another cost capacity is produced for boosting the likelihood of the locale inside the circle. The division of the picture is done utilizing a novel diagram seek calculation fit for recognizing the outskirts boosting the likelihood of the circle. The blend of diagram hunt and pixel order empowers us to fuse substantial capabilities into the cost capacity outline, which is basic for division of the optic plate.

Our results are affirmed against a reference standard of 82 datasets and appeared differently in relation to the manual divisions of 3 glaucoma associates.

[3] "Optic disk feature extraction via modified deformable model technique for glaucoma analysis," by J. Xu et al.

A deformable-model based methodology is exhibited in this paper for the discovery of optic container and glass edges. The strategy proposed will not evidence perfect shape o the container and the glass of the retinal channels. It shown accuracy rate of 94% . There was about 100 testing samples of the patients undertaken but it got failed in this methodology for some test cases. Hence the technique Heidelberg Tomography was implemented for glaucoma detection.

[4] "Optic disk and cup segmentation from monocular color retinal images for glaucoma assessment," by G. D. Joshi et al.

The examination of the optic disk is the preliminary step to be done for glaucoma detection. Then the manual testing ensures whether the patient is affected by glaucoma or not. A multistage system which covers a set of vessel twists that will make some manual examination of the retinal parts. The novel optic disk fragments incorporates picture of element space in the optic disk detection. It takes database of 138 pictures. It shows result of consistency over data sets but it gets quantitative analysis of optic disk fragments.

[5] "Classifying glaucoma with image-based features from fundus photographs," by R. Bock et al.

Classification of eye samples is essential factor when there will be huge samples of glaucoma affected patients. The status of glaucoma varies from patient to patient. There are many frameworks such as novel, deformable, state of art. If the disease is viewed from numerous perspectives it differs from consequences. The "vesselfree" which is a new methodology that gives middle accuracy which may add new facts for ophthalmologists to better analyze the glaucoma disease. It evidences 86% progress from a set of database having 200 image samples.

#### 4. CONCLUSION

The method achieves more accurate result compared to the earlier methods it can give exact picture of the status of disease and the future enhancement can be done for 3D retinal fundus images.

#### 5. REFERENCES

[1]. H. A. Quigley and A. T. Broman, "The number of people with glaucoma worldwide in 2010 and 2020," *Brit. J. Ophthalmol.*, vol. 90, no. 3, pp. 262–267, 2006.

[2] S. Y. Shen, "The prevalence and types of glaucoma in Malay people: The Singapore Malay eye study," *Investigative Ophthalmol. Vis. Sci.*, vol. 49, no. 9, pp. 3846–3851, 2008.

[3] P. J. Foster *et al.*, "The prevalence of glaucoma in Chinese residents of Singapore: A cross-sectional population survey of the Tanjong Pagar district," *Arch. Ophthalmol.*, vol. 118, no. 8, pp. 1105–1111, 2000.

[4] Centre for Eye Research Australia. (2008). Tunnel vision: The economic impact of primary open angle glaucoma. [Online]. Available: <http://nla.gov.au/nla.arc-86954>

[5] M. D. Abr`amoff *et al.*, "Automated segmentation of the optic disc from stereo color photographs using physiologically plausible features," *Investigative Ophthalmol. Vis. Sci.*, vol. 48, pp. 1665–1673, 2007.

[6] J. Xu *et al.*, "Optic disk feature extraction via modified deformable model technique for glaucoma analysis," *Pattern Recognit.*, vol. 40, pp. 2063–2076, 2007.